BSAVA BRITISH SMALL ANIMAL VETERINARY ASSOCIATION

PAPER

Modified semitendinosus muscle transposition to repair ventral perineal hernia in 14 dogs

E. Morello*, M. Martano*, S. Zabarino*, L. A. Piras*, S. Nicoli‡, R. Bussadori† and P. Buracco*

*Department of Veterinary Science, School of Veterinary Medicine University of Turin, Turin, Italy

†Clinica Veterinaria Gran Sasso, Milano, Italy

‡Clinica Veterinaria Roma Sud, Roma, Italy

Objectives: To describe a modified technique of semitendinosus muscle transposition for the repair of ventral perineal hernia.

Materials and Methods: Retrospective review of case records of dogs with ventral perineal hernia that were treated by transposing the medial half of the longitudinally split semitendinosus muscle of one limb. The transposition of the internal obturator muscle was used when uni- or bilateral rectal sacculation was also present in addition to ventral perineal hernia; colopexy and vas deferens pexy were also performed.

Results: Fourteen dogs were included. In addition to ventral perineal hernia, unilateral and bilateral perineal hernia was also present in five and six of the dogs, respectively. The mean follow-up time was 890 days. Ventral perineal hernia was successfully managed by the modified semitendinosus muscle transposition with minor complications in all the dogs included in the study.

Clinical Significance: Despite the small number of dogs included, the unilateral transposition of the medial half of the longitudinally split semitendinosus muscle consistently supported the ventral rectal enlargement in perineal hernia without obvious adverse effects.

Journal of Small Animal Practice (2015) **56**, 370–376
DOI: 10.1111/jsap.12342

Accepted: 7 January 2015; Published online: 3 March 2015

INTRODUCTION

Perineal hernia (PH) occurs because of weakness and separation of the pelvic diaphragm (Aronson 2012) resulting in rectal sacculation or dilatation (Niles & Williams 2005). Many factors may contribute to the degenerative changes of the pelvic diaphragm, including tenesmus (Head *et al.* 2002, Aronson 2012), pelvic musculature variations (male vs. female) (Aronson 2012), hormone influence (Mann *et al.* 1989, Mann *et al.* 1995, Merchav *et al.* 2005, Niebauer *et al.* 2005), and pelvic muscle atrophy due to neuropathy (Sjollema *et al.* 1993). The transposition of the internal obturator muscle (TIOM) is the most commonly recommended procedure to re-establish the pelvic diaphragm (Hardie *et al.* 1983). Other techniques have also been described (Burrows & Harvey 1973, Spreull & Frankland 1980, Stoll *et al.* 2002, Bongartz *et al.* 2005, Szabo *et al.* 2007, Lee *et al.* 2012, Pratummintra *et al.* 2013). In cases of PH with major rectal sacculation, PH recurrence, retroflexed bladder and/or prostate herniation, herniorrhaphy may be combined with colo-, cysto- and vas deferens pexy (Bilbrey *et al.* 1990, Brissot *et al.* 2004). PH may recur, especially in cases with muscle atrophy and/or ventral perineal hernia (VPH) (Orsher 1986). VPH, often associated with bilateral PH, is a rectal sacculation between the ischiourethralis, bulbocavernosus, and ischiocavernosus muscles (Aronson 2012). It represents a considerable challenge to the surgeon. If the degree of ventral sacculation is small, suturing the elevated obturator flap as far medially as possible is often satisfactory (Niles and Williams 2005). Larger ventral rectal defects can be managed with the semitendinosus muscle transposition (SMT), as reported in two cases (Chambers & Rawlings 1991).

It has been the authors' experience that standard SMT was not optimal for VPH repair. Subsequently an alternative to the full SMT through the median separation of the semitendinosus muscle (SSMT) was developed that appeared to be more useful and successful. The aim of this study was to describe this new technique and to report its efficacy and clinical outcome in a

JSAP JOURNAL OF SMALL ANIMAL PRACTICE

population of dogs affected with VPH. It was hypothesized that the SSMT would be successful in treating VPH.

MATERIALS AND METHODS

Inclusion criteria

Medical case records of dogs undergoing VPH repair with SSMT were reviewed (2007–2013). Only complete records with signalment, history, clinical presentation, treatment modalities, intra- and post-operative complications and a minimum of 6 months follow-up were included.

Pre-surgical evaluations

Work-up included a complete physical examination, blood cell count and serum chemistry profile, urinalysis, abdominal, scrotal, and, if needed, perineal (for bladder retroflexion and/or prostate herniation) ultrasound. Diagnosis of VPH was reached by rectal digital and perineal palpation, always performed by the same surgeon (PB). When ventral rectal sacculation was still present after colopexy and TIOM, SSMT was performed to give ventral rectal support.

Anaesthesia and pain management

After methadone administration [0.2 mg/kg intramuscularly (IM)] (Eptadone, Molteni Farmaceutici), anaesthesia was induced with propofol (Fresenius, Kabi) (4–8 mg/kg intravenously (IV) administered to effect) and maintained with isoflurane in oxygen. Analgesia was provided with target-controlled infusion of fentanyl (Fentanest, Pfizer). Pre-operative cefazolin (Cefazolina, TEVA) (22 mg/kg IV) was administered at anaesthesia induction, then every 90 minutes until completion of surgery.

Animal preparation and positioning and ancillary procedures

The skin of the abdomen, perineum, scrotum, tail base and thigh of one limb were clipped; rectum and anal sacs were digitally emptied and the urethra catheterised. When uni- or bilateral rectal sacculation/dilatation with marked rectal enlargement because of faecal accumulation was detected at pre-operative rectal digital exploration, colopexy and vas deferens pexy were also performed. For colopexy and vas deferens pexy or orchiectomy, dogs were placed in dorsal recumbency and the abdominal and scrotal skin aseptically prepared. At the end of the abdominal surgery, the dogs were positioned in sternal recumbency, with the pelvic limbs hanging over the edge of the surgical table (de Mello Souza & Mann 2013). At this point, before herniorrhaphy, the decrease of rectal sacculation as a result of colopexy was evaluated by digital exploration. The tail was fixed over the back and a purse-string suture was placed around the anus; then perineum, tail base and caudal thigh were aseptically prepared. In all the unilateral PH cases, the limb opposite the lateral rectal defect was clipped; the right limb was systematically prepared in all other cases (VPH only or bilateral PH).

Colopexy, vas deferens pexy, orchiectomy and herniorrhaphy were performed during the same anaesthesia. Colopexy consisted of descending colon cranial traction and left flank, 3–4 cm long, incisional musculo-muscular suture (Williams 2012); for vas deferens pexy each vas deferens was sutured to itself after passing it caudo-cranially through an ipsilateral abdominal wall muscular tunnel (Aronson 2012); 3/0–2/0 monofilament absorbable material (glycomer 631, Biosyn, Tyco Healthcare) was used for both procedures.

Perineal herniorrhaphy

Lateral PHs were repaired by TIOM (elevated with periosteum) (Aronson 2012) and VPHs by SSMT (see later). When combined with TIOM, SSMT was performed after completion of TIOM. Herniorrhaphy was always performed by the same surgeon (PB).

The skin incision was continued from the ventral end of TIOM incision or, if not combined with TIOM, approximately 3 cm lateral to the tail base, extending ventrally toward and across the midline up to the opposite ischiatic tuberosity. The incision was then continued distally along the contralateral caudal thigh, up to the popliteal area. In contrast to SMT, in which the entire muscle is transected proximal to the popliteal lymph node (Chambers & Rawlings 1991), the semitendinosus muscle was first isolated, then longitudinally and bluntly split in two parts with scissors, sparing both the proximal and distal vascular pedicles (proximally caudal gluteal artery and distally distal caudal femoral artery) (Fig 1). Then only the medial part of the muscle was transected distally, proximal to the popliteal lymph node (Fig 2). The distal stump was sutured to the intact lateral muscular half, whose fascia was opposed with a simple continuous suture (Fig 3). The transected split muscle was rotated medially, passing ventral to the anus up to the opposite lateral perineum (Figs 3 and 4). The distal end of the flap was sutured to either the coccygeus muscle and/or the sacrotuberous ligament (Figs 3 and 4), the medial border of the flap to the ventro/lateral aspect of the

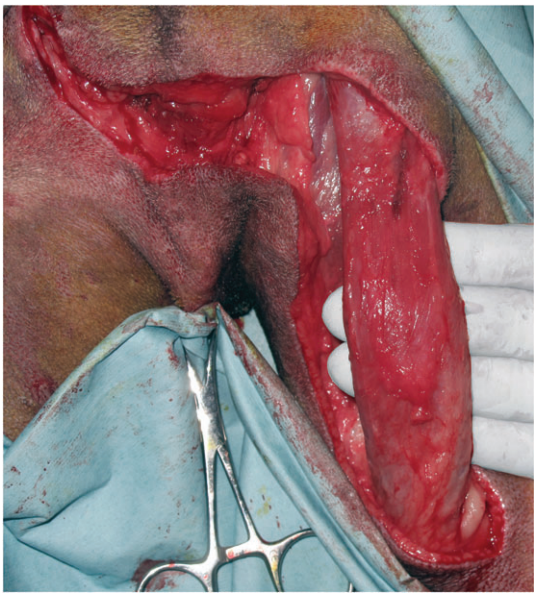

FIG 1. Intraoperative view of the blunt dissection of the semitendinosus muscle from the adjacent structures

FIG 2. The muscle is longitudinally and bluntly split in two parts, in this modified technique. The medial part of the muscle is then transected distally, close to the popliteal lymph node (dotted black line), the lateral half remains intact in its anatomic position

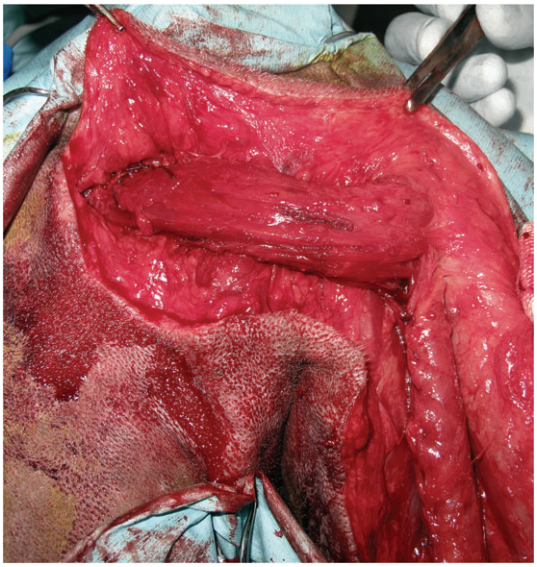

FIG 3. Intraoperative view of the medial rotation of the split muscle, passing beneath the anus up to the lateral perineum of the opposite site

external anal sphincter, while the lateral border to the internal obturator muscle (elevated in case of TIOM), ischiourethralis and bulbospongiosus muscles (taking care to avoid the urethra) and fascia of the dorsal border of the ipsilateral ischiatic tuberosity (Figs 3 and 4). A 3/0–0 monofilament absorbable suture material was used (glycomer 631, Biosyn) in an interrupted pattern. Drains were not used.

A rectal examination was performed after procedure completion to assess the reestablishment of rectal wall support and to ascertain that no sutures had penetrated the rectal lumen.

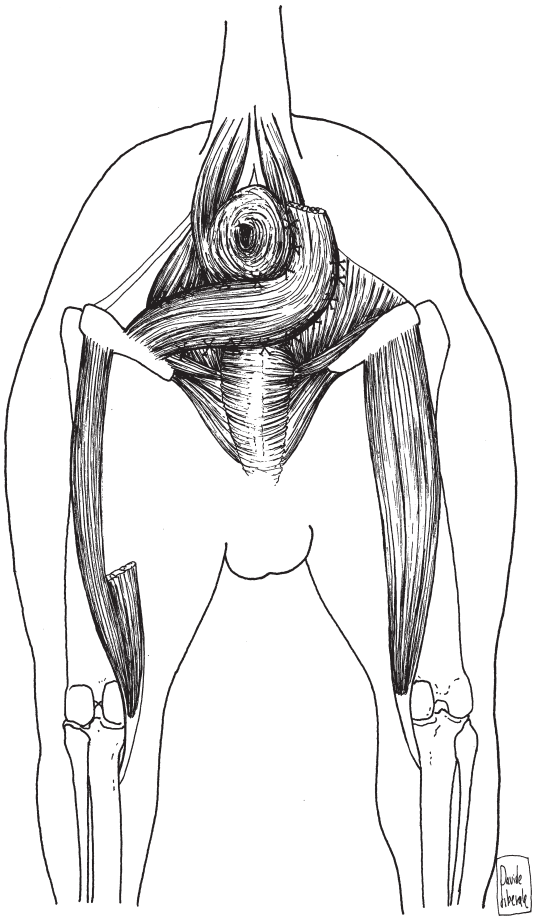

FIG 4. Schematic artwork of the surgical technique proposed in the present paper. The transected medial part of the split muscle is rotated medially, passing beneath the anus up to the lateral perineum of the opposite site. After rotation, the distal end of the muscle is sutured to the coccygeus muscle and/or to the sacrotuberosous ligament. The medial border of the muscle is sutured on both the lateral aspects of the anus to the ventro/lateral aspect of the external anal sphincter, while its split border is sutured to the internal obturator muscle (elevated in the case of TIOM), the ischiourethralis and bulbospongiosus muscles (on the sagittal plane), the fascia of the dorsal border of the omolateral ischiatic tuberosity and the perineal fascia

Post-operative care

All dogs received buprenorphine (Temgesic, Schering-Plough) post-operatively [10 µg/kg 6- to 8-hourly, subcutaneously (SC)] for 48–72 hours. Metronidazole (Flagyl, Zambon) [10 mg/kg 12-hourly, per os (PO)] and amoxicillin/clavulanic acid (Amoxicillina/ac clavulanico, TEVA) (22 mg/kg 12-hourly, PO) were administered for 7–10 days. Carprofen (Rimadyl, Pfizer) (2.2 mg/kg 12-hourly, PO) was given for 7 days. An Elizabethan collar was placed. At discharge, owners were advised to feed the dog with a low-residue diet for the first 30 days.

Follow-up

Dogs were re-examined for early and late post-operative complications and long-term outcome. For long-term follow-up (≥6 months), attention was focused on PH recurrence, determined both by clinical signs and digital rectal examination. Tenesmus, faecal and/or urine incontinence, rectal prolapse and

Table 1. Signalment, clinical signs at presentation, ultrasound examination findings, treatment modalities and outcome of the 14 dogs included in the present retrospective case series

Case no	Breed	Weight (kg)	Age (yy)	Sex	Clinical signs at presentation	Previous surgery (herniorrhaphy and ancillary procedures)	Ultrasound examination findings	PH Side	Current surgery	Follow up (days)	Post-surgical complication	PH recurrence
1	Mixed	7	9	MC	Tenesmus, dyschezia with fecal impaction, perineal swelling	COLP, OR, DEFP, L R TIOM	NR	V	R SSMT	1033	Persistent tenesmus	N
2	Mixed	10	9	MC	Tenesmus, dyschezia with fecal impaction, perineal swelling	OR, R L SPH	NR	L, R, V	COLP, DEFP, R SSMT, L R TIOM	731	None	Y, L and R
3	Maltese	8	10	MI	Tenesmus, dyschezia with fecal impaction, perineal swelling	N	Enlarged prostate	R, V	OR, DEFP, COLP, L SSMT, R TIOM	1237	None	N
4	Pekingese	8	9	MI	Tenesmus, dyschezia with fecal impaction, perineal swelling	N	NR	R, V	OR, L SSMT, R TIOM	1133	Persistent tenesmus	N
5	Mixed	35	7	MC	Tenesmus, dyschezia with fecal impaction, perineal swelling	L TIOM, OR, OM prostatic abscess	NR	R, L, V	R SSMT, R L TIOM	724	None	N
6	Mixed	32	10	MC	Tenesmus, dyschezia with fecal impaction, perineal swelling	COLP, DEFP, OR, L R TIOM	NR	V	R SSMT	1024	Post-operative rectal prolapse	N
7	German shepherd	34	8	MI	Tenesmus, dyschezia with fecal impaction, perineal swelling	N	Testicular tumor	R, L, V	COLP, DEFP, R SSMT, L R TIOM, OR	582	Wound dehiscence, slight lameness	N
8	American bull dog	22	7	MC	Tenesmus, dyschezia with fecal impaction, perineal swelling	OR, COLP, DEFP, R L SPH	NR	R, L, V	R SSMT, R L TIOM	708	Wound dehiscence, slight lameness	Y, L
9	Siberian husky	25	14	MI	Tenesmus, dyschezia with fecal impaction, perineal swelling	N	Paraprostatic cyst	L, V	OR, COLP, DEFP, R SSMT, L TIOM, paraprostatic cyst OM	1133	None	N
10	Collie	22	8	MC	Tenesmus, dyschezia with fecal impaction, perineal swelling	L SPH, OR	NR	L, V	R SSMT, L TIOM	752	Wound dehiscence	N
11	German shepherd	33	9	MI	Tenesmus, dyschezia with fecal impaction, perineal swelling	N	NR	R, L, V	OR, COLP, DEFP, R SSMT, R L TIOM	1142	None	N
12	Hovawart	37	9	MI	Tenesmus, dyschezia with fecal impaction, perineal swelling	N	NR	R, L, V	OR, COLP, DEFP, R SSMT, R L TIOM	914	None	N
13	Maltese	12	14	MC	Tenesmus, dyschezia with fecal impaction, perineal swelling	L SPH, OR	NR	L, V	L TIOM, R SSMT	713	None	N
14	Bolognese	11	6	MC	Tenesmus, dyschezia with fecal impaction, perineal swelling	R L TIOM, COLP, OR, DEFP	NR	V	R SSMT	639	None	N

M Male, C castrated, I intact, L left, R right, V ventral, SSMT split semitendinosus muscle transposition, COLP colopexy, OR orchiectomy, DEFP vas deferens pexy, TIOM transposition internal obturator muscle, OM omentalization, PH perineal hernia, SPH standard herniorraphy by simple muscle apposition, NR nothing relevant, N no, Y yes

lameness were classified as transient or persistent when present for less or more than 6 post-operative months, respectively.

Physical, rectal and limb function were evaluated at 7, 15 and 30 days from hospital discharge. Thereafter, the dogs were re-revalued by the referring veterinarians every 3 months in the first post-operative year and every 6 months thereafter. When PH recurrence was suspected or lameness noted, the dogs were re-checked by the surgeon (BP).

RESULTS

Signalment – clinical findings

Fourteen dogs were included. Median age was 9 years (range 6–14; mean 9.2); median weight was 22 kg (range, 7–37; mean 21.1). All the dogs were male. The affected breeds as well as clinical signs at presentation (mean duration 153.5 days, range 95–201, median 159.5) are reported in Table 1. Preoperatively, none of the dogs showed pre-existing orthopaedic problems.

Previously performed surgeries and abdominal ultrasound findings are reported in Table 1.

At presentation, in addition to VPH (Fig 5), three dogs had a left-sided PH, two a right-sided PH and six a bilateral PH (Table 1).

Ancillary procedures

Colopexy and vas deferens pexy were performed just before herniorrhaphy in six dogs (Table 1). The preoperatively diagnosed paraprostatic cyst (Table 1) was treated by partial cyst wall resection and omentalization. Orchiectomy was performed simultaneously to herniorrhaphy in six dogs (Table 1).

FIG 5. Clinical evidence of severe ventral rectal sacculation at digital rectal examination

Histology of all testicles removed was available and revealed an interstitial cell tumour in one dog (Table 1). Histology of the enlarged prostate on a tissue sample collected during abdominal surgery revealed benign prostatic hyperplasia (Table 1).

Perineal herniorrhaphy

In 5 and 6 dogs (Table 1) unilateral and bilateral TIOM was performed, respectively. Right (1, 2, 5, 6, 7, 9, 10, 11, 12, 13, 14) or left (3, 4, 8) SSMT was performed.

Post-operative digital rectal examination confirmed the resolution of PH in all the dogs and the absence of sutures penetrating the rectal wall.

Complications

Partial wound dehiscence occurred in three dogs (Table 1) at the dorsal aspect of the SSMT incision; healing was achieved on a twice-a-day sterile saline solution wound cleaning basis; antibiotics (amoxicillin/clavulanic acid, 22 mg/kg 12-hourly, PO; metronidazole, 10 mg/kg 12-hourly, PO) were continued for 10 days. Some swelling at the caudal thigh and perineum was observed in all cases; spontaneous resolution occurred within the first post-operative examination (7 days). Post-operative limb function appeared normal in 11 dogs; in two dogs (n. 7, 8) a persistent (≥6 months) grade I (subtle, intermittent weight-bearing lameness) (Anderson *et al.* 2002) painless lameness was evident. Neurological and orthopaedic examinations performed post-operatively were normal.

Post-operative tenesmus occurred in all dogs. It was transient (spontaneous resolution within 7–15 days) in 12 cases and long lasting but intermittent (>6 months) in two dogs (Table 1). Rectal prolapse occurred in one dog (Table 1), despite colopexy and herniorrhaphy; this was treated 1 month after herniorrhaphy by partial rectal amputation (Aronson 2012).

Outcome

Median follow-up time was 833 days (range 582–1237; mean 890). No PH recurrence was detected at 7, 15 and 30 days. A long-term PH recurrence with recurrence of tenesmus and perineal swelling was detected on rectal examination in two dogs (Table 1), at 731 and 527 days, respectively. Recurrence occurred bilaterally (Table 1) or on the opposite site from SSMT (Table 1). Owners refused further treatment. VPH never recurred. At the time of writing 11 dogs are still alive (median 914; range 582–1237 days); 1 dog (2) was lost to follow-up after 731 post-operative days and 2 dogs (5, 9) died of unrelated causes (hit by a car, old age) after 724 and 1133 days, respectively.

DISCUSSION

It was hypothesized that SSMT would be useful to treat VPH in dogs. In the present study, all 14 dogs clinically affected with VPH were successfully treated with SSMT. Recurrence occurred in two dogs, but only on the lateral component of their PH.

Factors negatively influencing the outcome of surgical repair include bilateral and ventral rectal sacculation (Burrows & Harvey

1973, Orsher & Johnston 1985), previous surgeries (Brissot *et al.* 2004), marked rectal faecal impaction (Brissot *et al.* 2004) and concurrent prostatic disease (Brissot *et al.* 2004). Eight out of 14 dogs in this study had already been surgically treated elsewhere for PH on one or multiple occasions, one dog had an enlarged prostate, and one had a paraprostatic cyst; marked rectal sacculation with faecal accumulation was present in all cases.

TIOM is the recommended treatment for PH with lateral rectal sacculation (Szabo *et al.* 2007) but difficulties in restoring the pelvic diaphragm have been reported because of muscle atrophy, VPH or PH recurrence after TIOM (Burrows & Harvey 1973, Hardie *et al.* 1983, Orsher, 1986). In cases of VPH, the defect can be only partially repaired by suturing the two internal obturator muscles at the midline (Chambers & Rawlings 1991), while a ventral rectal support has been successfully provided by semitendinosus muscle transposition (Chambers & Rawlings 1991).

The semitendinosus muscle has most of the features required for a vascularised muscular transposition flap (Mortari *et al.* 2005). To the authors' knowledge, no large case series dealing with SMT for VPH repair in dogs has been published so far. The procedure is reported in some veterinary surgical textbooks (Niles & Williams 2005, Aronson 2012), and it has been published as an experimental work (Mortari *et al.* 2005) and as a case report in two dogs (Chambers & Rawlings 1991).

In this study, it was proposed to transpose the muscle to fill in the ventral perineal defect according to a modified technique based on the unilateral transposition of the medial half of the longitudinally split semitendinosus muscle. The rationale to modify the standard SMT was that in some dogs (not presented here) having a thick semitendinosus muscle, redundancy did not allow a proper tension to ensure an adequate ventral rectal support, while the modified technique resulted in a subjectively better result, and it became the preferred technique at the authors' institution in selected cases. In particular, the post-operative rectal examination of the dogs treated by SSMT revealed subjectively a consistent ventral rectal support in all cases; furthermore, the lateral support was subjectively much stronger when SSMT was combined with TIOM on the same side.

Colopexy and vas deferens pexy were performed during the same anaesthetic procedure for herniorrhaphy. According to previous studies (Brissot *et al.* 2004), colopexy contextually to herniorrhaphy partially resolved the rectal deviation also in this study, thus making herniorrhaphy easier. When judged appropriate, vas deferens pexy was useful for stabilizing both the prostate gland and bladder neck (Bilbrey *et al.* 1990).

Partial surgical wound dehiscence was observed in three dogs (21%). This is commonly observed after PH repair (4–26%) (Orsher 1986, Hosgood *et al.* 1995, Brissot *et al.* 2004, Szabo *et al.* 2007, Niles & Williams 2005). A higher incidence is reported after semitendinosus muscle transposition (40%) because of faecal contamination and extensive surgical dissection (Mortari *et al.* 2005). The cause of dehiscence was not further investigated in the present study because second intention healing was easily achieved.

Normal limb function has been reported by Mortari *et al.* (2005) after complete semitendinosus muscle transposition. In the present study, limb use did not appear to be subjectively affected by the procedure in all but two dogs (14%), in which a persistent grade I and painless lameness was noted. In these two dogs, preoperative limb function was normal; when these dogs were re-evaluated for this slight lameness, both neurological and orthopaedic examinations were normal.

A long lasting but intermittent tenesmus was observed in two dogs (14%). Tenesmus is a reported complication after perineal herniorrhaphy (8–44%) (Hosgood *et al.* 1995, Brissot *et al.* 2004, Szabo *et al.* 2007, Grand *et al.* 2013). Causes of persistent post-operative tenesmus have not been exactly determined. Rectal deformations associated with persistent recto-colitis, colo-rectal hypomotility due to long-term straining and a possible influence of colopexy have been suggested (Hosgood *et al.* 1995).

PH recurrence occurred in two dogs (14%); it was evident bilaterally in one dog and on the side opposite to previous SSMT in the other. However, in both dogs, the ventral rectal support was still present at rectal examination. Recurrence is a reported complication after perineal herniorrhaphy with TIOM (10–20%) (Niles & Williams 2005, Brissot *et al.* 2004, Szabo *et al.* 2007, Grand *et al.* 2013). A higher risk of recurrence and worse prognosis has been associated with bilateral, ventral and complicated hernias (Orsher 1986, Brissot *et al.* 2004).

Rectal prolapse occurred in one dog (7%) after herniorrhaphy. This complication can develop after reconstruction of the pelvic diaphragm in cases of both bilateral and ventral PH (9–17%) (Hosgood *et al.* 1995, Bongartz *et al.* 2005, Aronson 2012). Partial rectal amputation was needed and curative in this dog.

In a previous study electromyography showed that the transposed semitendinosus muscle was still able to contract, but atrophy was detected by both ultrasonography and morphological analysis within its distal part (Mortari *et al.* 2005). Neither ultrasound nor electromyography was performed in the present study. Nevertheless, the low number of recurrences recorded suggests that, if atrophy was present, it did not prevent SSMT from functioning as a support to the rectum.

The long-term results presented in this retrospective case series suggest that (a) the semitendinosus muscle can be safely longitudinally split, (b) the transposition of half of the muscle was enough to adequately fill in the ventral pelvic diaphragm defect, (c) the SSMT achieved long term support of the ventral aspect of the rectum.

This study provides evidence that SSMT can be used to sustain the rectum ventrally in case of severe VPH, but further studies involving more dogs are warranted. It is also believed that a comparison with dogs treated by transposing the entire muscle (standard SMT technique) may be useful.

Acknowledgements

The authors would like to thank prof. Paolo Belgioioso (Accademia Albertina di Belle Arti di Torino. Scuola di Anatomia Artistica. Corso di Illustrazione Scientifica) and his student Davide Liberale who drew the schematic representation of the proposed new surgical technique.

Conflict of interest

None of the authors of this article has a financial or personal relationship with other people or organisations that could inappropriately influence or bias the content of the paper.

References

Anderson, G. M., Lewis, D. D., Radasch, R. M., *et al.* (2002) Circular external skeletal fixation stabilization of antebrachial and crural fractures in 25 dogs. *Journal of The American Animal Hospital Association* **39**, 479-498

Aronson, L. R. (2012) Rectum, anus and perineum. In: Veterinary Surgery Small Animal. Eds K. M. Tobias and S. A. Johnston. Saunders, Philadelphia, PA, USA. pp 1564-1600

Bilbrey, S. A., Smeak, D. D., & DeHoff, W. (1990) Fixation of the deferent ducts for retrodisplacement of the urinary bladder and prostate in canine perineal hernia. *Veterinary Surgery* **19**, 24-27

Bongartz, A., Carofiglio, F., Balligand, M., *et al.* (2005) Use of autogenous fascia lata graft for perineal herniorrhaphy in dogs. *Veterinary Surgery* **34**, 405-413

Brissot, H. N., Duprè, G. P., & Bouvy, B. M. (2004) Use of laparotomy in a staged approach for resolution of bilateral or complicated perineal hernia in 41 dogs. *Veterinary Surgery* **33**, 412-421

Burrows, C. F., & Harvey, C. E. (1973) Perineal hernia in the dog. *Journal of Small Animal Practice* **14**, 315-332

Chambers, J. N., & Rawlings, C. A. (1991) Applications of a semitendinosus muscle flap in two dogs. *Journal of The American Veterinary Medical Association* **199**, 84-86

de Mello Souza, C. H., & Mann, T. (2013) Perineal hernias. In: Small Animal Soft Tissue Surgery. Ed E. Monnet. Wiley-Blackwell Saunders, Ames, IA, USA. pp 286-296

Grand, J. G., Bureau, S., & Monnet, E. (2013) Effects of urinary bladder retroflection and surgical technique on postoperative complication rates and long term outcome in dogs with perineal hernia: 41 cases (2002-2009). *Journal of The American Veterinary Medical Association* **243**, 1442-1447

Hardie, E. M., Kolata, R. J., Earley, T. D., *et al.* (1983) Evaluation of internal obturator muscle transposition in the treatment of perineal hernia in dogs. *Veterinary Surgery* **12**, 69-72

Hosgood, G., Hedlund, C. S., Pechman, R. D., *et al.* (1995) Perineal herniorrhaphy: perioperative data from 100 dogs. *Journal of The American Animal Hospital Association* **31**, 331-342

Lee, A. J., Chung, W. H., Kim, D. H., *et al.* (2012) Use of canine small intestinal submucosa allograft for treating perineal hernias in two dogs. *Journal of Veterinary Science* **13**, 327-330

Mann, F. A., Boothe, H. W., Amoss, M. S., *et al.* (1989) Serum testosterone and estradiol 17-beta concentration in 15 dogs with perineal hernia. *Journal of The Veterinary Medical Association* **194**, 1578-1580

Mann, F. A., Nonneman, D. J., Pope, E. R. *et al.* (1995) Androgen receptors in the pelvic diaphragm muscles of dogs with and without perineal hernia. *American Journal of Veterinary Research* **56**, 134-139

Merchav, R., Shamay, A., Feuerman, Y., *et al.* (2005) Expression of relaxin receptor LRG7, canine relaxin, and relaxin-like factor in the pelvic diaphragm musculature of dogs with and without perineal hernia. *Veterinary Surgery* **34**, 476-481

Mortari, A. C., Rahal, S. C., Resende, L. A., *et al.* (2005) Electromyographical, ultrasonographical and morphological modifications in semitendinosus muscle after transposition as ventral perineal muscle flap. *Journal of Veterinary Medicine. A, Physiology, Pathology, Clinical Medicine* **52**, 359-365

Niebauer, G. W., Shibly, S., Seltenhammer, M., *et al.* (2005) Relaxin of prostatic origin might be linked to perineal hernia formation in dogs. *Annals of the New York Academy of Science* **1041**, 415-422

Niles, J. D., & Williams, J. M. (2005) The large intestine and rectum. In: BSAVA Manual of Canine and Feline Abdominal Surgery. Eds J. D. Niles and J. M. Williams. BSAVA, Gloucester. pp 125-167

Orsher, R. J., & Johnston, D. E. (1985) The surgical treatment of perineal hernia in dogs by transposition of the obturator muscle. *The Compendium on Continuing Education* **7**, 233-239

Orsher, R. J. (1986) Clinical and surgical parameters in dogs with perineal hernia. Analysis of results of internal obturator transposition. *Veterinary Surgery* **15**, 253-258

Pratummintra, K., Chuthatep, S., Banlunara, W., *et al.* (2013) Perineal hernia repair using an autologous tunica vaginalis communis in nine intact male dogs. *Journal of Veterinary Medical Science* **75**, 337-341

Sjollema, B. E., Venker-va Haagen, A. J., van Sluijs, F. J., *et al.* (1983) Electromyography of the pelvic diaphragm and anal sphincter in dogs with perineal hernia. *American Journal of Veterinary Research* **54**,185-190

Spreull, J. S. A., & Frankland, A. L. (1980) Transplanting the superficial gluteal muscle in the treatment of perineal hernia and flexure of the rectum in the dog. *Journal of Small Animal Practice* **21**, 265-278

Stoll, M. R., Cook, J. R., Pope, E. R., *et al.* (2002) The use of porcine small intestinal submucosa as a biomaterial for perineal herniorrhaphy in the dog. *Veterinary Surgery* **31**, 379-390

Szabo, S., Wilkens, B., & Radasch, R. (2007) Use of polypropylene mesh in addition to internal obturator transposition: a review of 59 cases (2000-2004). *Journal of The American Animal Hospital Association* **43**, 136-142

Williams, J. M. (2012) Colon. In: Veterinary Surgery Small Animal. Eds K. M. Tobias and S. A. Johnston. Saunders, Philadelphia, PA, USA. pp 1542-1563